

Management of Spontaneous Coronary Artery Dissection: when doing less is more

Dr Evelyn Brown

Cardiology Registrar

University Hospital of North Tees, Stockton-on-Tees

Introduction

Spontaneous coronary artery dissection (SCAD) is increasingly recognised as an important cause of acute coronary syndrome (ACS), particularly in young and middle-aged women. However, management is distinct from ACS due to atherosclerotic disease. There is a limited evidence base for acute and longer term management and data is entirely based on retrospective and observational studies, with no large scale

randomised controlled trials. Based on this limited data and largely expert consensus, position statements have been published by the American Heart Association (1) and the European Society of Cardiology (2). Most recently, a large international cohort study was published in 2021 (3) looking at the role of percutaneous coronary intervention (PCI) in SCAD. This editorial will focus on diagnosis and management, outlining current guidelines and evidence and future areas for research.

Epidemiology

SCAD has historically been underdiagnosed, but with increasing recognition in recent years is estimated to cause up to a third of all ACS cases in women aged less than 50 years (4). However, estimating prevalence in population based studies has been limited by incomplete clinical data and inconsistent angiographic criteria (5). SCAD is also the most common cause of pregnancy-associated ACS (6).

Take Home Messages

- Clinically stable patients should be managed conservatively with a period of inpatient monitoring
- Invasive angiography is the mainstay of diagnosis, but carries increased risks of extending existing dissection or causing iatrogenic dissection
- Revascularisation is high risk and is primarily indicated in patients with ongoing ischaemia, arrhythmias, cardiogenic shock, or possibly left main stem or proximal disease
- There is no strong evidence for long term therapy to prevent recurrence, or for antiplatelets outside the context of PCI
- SCAD is associated with underlying arteriopathies, most commonly fibromuscular dysplasia, so screening for extra-coronary vascular abnormalities with CT or MR should be considered

Pathophysiology

There are two main hypotheses (2, 5) for the pathophysiology of SCAD. One describes an ‘inside-out’ theory whereby the spontaneous development of a dissection flap allows blood to enter the sub-intimal space from vessel lumen. The alternative hypothesis is an ‘outside-in’ model when formation of a spontaneous haematoma within the vessel media compresses blood flow within the true lumen. This could occur from disruption of microvessels within the vessel wall. The ‘outside-in’ theory is supported by most SCAD cases not showing a communication between true and false lumens on angiography, and serial imaging showing intramural haematoma formation prior to intimal dissection (7). Additionally optical coherence tomography (OCT) imaging suggests that the false lumen is under pressure, and it is rupture of this haematoma that forms the communication with the true lumen (8).

Given the overwhelmingly increased prevalence in women, and association with pregnancy, SCAD is likely to be related to sex hormones but an exact mechanism has not been found (2). There is no evidence currently to suggest that SCAD is related to contraceptive hormone use or postmenopausal hormone replacement therapy (5).

SCAD has a well-documented association with underlying arteriopathies, most commonly fibromuscular dysplasia (1, 9), as well as connective tissue disorders and systemic inflammatory conditions. In addition, there does appear to be a familial preponderance, and the lack of traditional cardiovascular risk factors in this patient group would also support a genetic basis for the condition, despite the lack of a strongly familial monogenic pattern of inheritance (1, 5).

Clinical presentation

Patients with SCAD usually present with typical ACS symptoms of chest pain, diaphoresis, and shortness of breath. They can also present in acute heart failure, with arrhythmias, or in cardiac arrest. One retrospective study looking at 53 SCAD patients with ST elevation MI (STEMI) among a cohort of 5208 consecutive STEMI patients (10), SCAD patients were more likely than those with atherosclerotic disease to develop cardiogenic shock, or have left main stem (LMS) or left anterior descending (LAD) disease.

Often SCAD patients lack traditional cardiovascular risk factors, but these are not completely absent; studies have shown a similar prevalence of hypertension and hyperlipidaemia to age- and sex-matched populations (1, 5). Nevertheless, a high index of suspicion is required to consider SCAD in these cases who are usually not 'typical' ACS patients. Cases are often associated with extreme physical or emotional stress (5), interestingly in male patients SCAD appears more related to extreme exertion, whereas women more commonly report extreme emotional stress (9).

The vast majority of patients will have elevated biomarkers and acute ECG changes, which may be ST elevation or non-ST elevation. Differentials in this patient group include atherosclerotic ACS, as well as Takotsubo cardiomyopathy, coronary thromboembolism, and myocardial infarction with non-obstructive coronary arteries.

Diagnosis of SCAD

Angiography

The mainstay of investigation is invasive angiography (1, 2, 5), although due to the fragile nature of the coronary vessels in SCAD this procedure carries considerably higher risks than in a non-SCAD population. In one study of 168 SCAD patients undergoing diagnostic angiography, there were (9) three iatrogenic dissections, two involving the left main stem. Notably all three patients had their angiograms via the radial route, whereas none of the 126 patients who had procedures performed via the femoral route had an iatrogenic dissection, suggesting that consideration should be given to femoral access in patients with suspected SCAD. Additionally, deep catheter engagement, non-coaxial positioning, and strong contrast injections should be meticulously avoided due to the risk of worsening an existing SCAD or causing iatrogenic dissection (1).

Angiographic appearances of SCAD are quite different to those of iatrogenic dissection, such as a radiolucent flap or dye hold up (2). SCAD tends to affect mid to distal coronary arteries, and most commonly the left anterior descending artery (2, 5). Usually, the other coronary vessels are normal, unlike in atherosclerotic disease, although multi-vessel SCAD can occur in 5 to 10% patients (2, 9, 11). The appearance of coronary tortuosity (12) and lack of intraluminal thrombus also favour SCAD, and often side branches are seen to form the boundaries of the false lumen.

The most widely adopted angiographic classification is by Saw (13) which describes three patterns of SCAD (table 1). Type 2 lesions are the most common, comprising around two thirds of cases (9).

Type 1	Multiple radiolucent lumens or arterial wall contrast staining
Type 2	Diffuse long smooth narrowing.
Type 3	Shorter focal stenosis, mimicking the appearance of atherosclerosis and often not possible to differentiate between atherosclerosis and SCAD, requiring intracoronary imaging

Table 1: Angiographic classification of SCAD (13).

The ESC position statement (2) also describes Type 4 SCAD which is complete vessel occlusion, which usually occurs in distal vessels.

SCAD can be difficult to diagnose on angiography, and may be misdiagnosed as atherosclerosis, spasm, or normal coronaries. If appearances are unclear, intracoronary imaging, nitrates or other imaging modalities can aid diagnosis (5).

Intracoronary imaging plays an important role, particularly in type 3 lesions or when PCI is being considered. However, it carries risks beyond the already increased risk of diagnostic angiography in these patients, mainly of extending dissection with the wire or catheter, or during contrast injection (1). It is advised to limit assessment to the proximal part of the lesion to minimise complications (2, 5). Overall OCT images provide better resolution than IVUS (1, 5) for imaging intimal tears and false lumens. However the advantage of IVUS is that less pressurised contrast injection is required (2) than for OCT.

Other imaging techniques

Cardiac magnetic resonance imaging can also support a diagnosis of SCAD by illustrating delayed gadolinium enhancement in the corresponding territory of suspected dissection (5), or suggest an alternative diagnosis such as myocarditis. A normal CMR however may not exclude SCAD (14).

CT coronary angiography is increasingly used in low and intermediate risk acute chest pain patients, but is of limited use in acute SCAD patients as a normal CT does not rule out the diagnosis (1). CT has relatively limited spatial resolution of small vessels where dissection is most likely to occur, and it is more likely that haematomas or abrupt changes in vessel calibre will be seen rather than dissection planes (5). No large scale studies have been carried out to determine the specificity or sensitivity of CT in acute SCAD (2, 5). However, CT may be useful as a follow up tool to confirm healing, especially where there is dissection in proximal vessels, and to avoid a further invasive test (2, 15).

Acute management

Revascularisation

The aim of acute management is to restore myocardial perfusion and blood flow in order to prevent further short and longer term complications. Current literature recommends conservative therapy in clinically stable patients (1, 2, 5, 11); unlike in atherosclerotic ACS patients, there is a significantly higher risk of PCI complications, and observational data suggests that SCAD often tends to heal without intervention. One prospective study (16) looked at 156 conservatively-managed SCAD patients with 182 non-contiguous lesions including 46.7% with less than TIMI flow 3, who underwent repeat angiography at a median of 154 days. 95% of those who had repeat angiography >30 days after the index event demonstrated angiographic healing.

For conservatively managed SCAD patients a longer period of inpatient monitoring (between three and five days) is recommended than for standard ACS patients (1, 5), as between 5-10% (5, 9) can develop early complications requiring emergency treatment and revascularisation. Figure 1 outlines the approach to management for different groups of SCAD patients based on current evidence and guidelines.

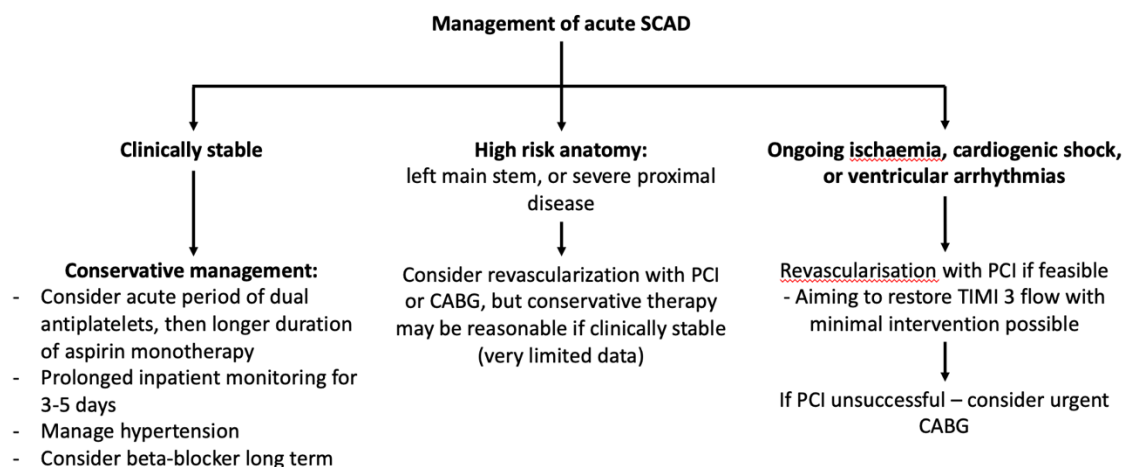


Figure 1: Summary of approach to management of SCAD patients, based on current evidence and guidelines (5, 1, 2, 11, 16, 9, 3). Flowchart adapted from Hayes et al 2018 (1).

PCI is considered for high risk patients: those with evidence of ongoing ischaemia, cardiogenic shock, ventricular arrhythmias, or high risk anatomy such as left main stem dissection (16, 11, 5, 1). There are no randomised controlled trials looking at revascularisation in SCAD patients. Particularly in stable patients with high risk anatomy, it is unclear if PCI is of benefit. However, an international cohort study published last year (3) looked at 215 SCAD patients who underwent PCI, matched with a cohort of 221 conservatively-managed SCAD patients, and found that more than 90% of patients undergoing PCI had ST elevation, TIMI 0 or 1 flow, or proximal dissections. These were also high risk PCI procedures with one third requiring either unplanned LMS stenting, more than three stents, or more than or equal to 50mm stent length, and despite this nearly two thirds had residual area of unstented dissection.

There is a significantly higher risk of PCI complications or failure in SCAD patients, quoted as between 38.6% (3) and 53% (11) in various studies. In addition to the risks of the diagnostic angiogram, passing the coronary wire carries risk of extending the dissection, and the fragile nature of the vessels and intramural haematoma makes PCI unpredictable. During PCI, haematomas can spread requiring multiple and longer stents (5) with increased long term risk in-stent thrombosis or restenosis. Conversely, later haematoma resorption can lead to stent malapposition (5). The cohort study from Kotecha et al in 2021 (3) found that PCI in this group of SCAD patients required on average an extra 0.7 stents and 21.4mm stent length compared to BCIS national audit data (17) for PCI for all causes. This study also found an increased frequency of complications with type 2 dissections; the authors suggest that the presence of fenestrations between the true and false lumens allow decompression of the haematoma and reduce risk of PCI complications.

There are no comparative studies of PCI strategies for SCAD, but a number of techniques have been suggested (1, 18-21), including using long stents to exceed the lesion edges by 5-10mm in order to cover areas of spreading haematoma when the stent is dilated. Alternatively, stenting the distal and proximal edges first to prevent propagation has been suggested, as well as stenting directly without pre-dilatation. Cutting balloons have also been used to fenestrate intramural haematoma and allow decompression (18). Some also advise not using stents but instead performing balloon angioplasty alone, or using bioresorbable stents. Overall the literature suggests that unlike in atherosclerotic disease, the 'focus should be less on restoring normal coronary architecture and more on the minimal measures required to restore TIMI flow grade 3' (5).

Despite the increased risks of PCI in SCAD patients, Kotecha et al (3) found that over a median follow up of 900 days there was no difference in major adverse cardiovascular and cerebrovascular events between the PCI cohort and the conservatively managed cohort. Also PCI in the majority of patients resulted in improved TIMI flow. Longer term data would be useful to look at the outcomes of extensive PCI in this young patient group with a median age in the late forties.

Coronary artery bypass grafting (CABG) is reserved for patients with ongoing ischaemia, ventricular arrhythmias or cardiogenic shock where PCI is extremely high risk or has been unsuccessful (1, 5). Most commonly this will involve lesions affecting the left main stem. CABG is complicated by difficulty grafting onto dissected and friable vessels, particularly as the dissection often affects the distal vessel. One retrospective study (11) looked at twenty patients undergoing in-hospital CABG for SCAD, and found a 5% early mortality rate, but a similar 5 year rate of recurrent SCAD or need for further revascularisation of the target vessel compared to those treated conservatively. Notably repeat angiography performed on eleven CABG patients at a median of 3.5 years found that only five out of sixteen bypass grafts remained patent, further supporting the notion that restoration of normal coronary flow can occur over time without intervention and this can lead to bypass graft failure.

Medical therapy

Medical therapy after SCAD aims to relieve symptoms, prevent complications, and prevent recurrence of SCAD. National and international guidelines should be followed for management of LVSD, and for antiplatelets after PCI. Evidence for therapy outside of these indications is based on retrospective and observational data.

There is no consensus for antiplatelet therapy in conservatively managed patients (5), with no evidence showing benefit of routine dual antiplatelet therapy as for atherosclerotic ACS patients. There is an argument for limiting antiplatelet use not only due to lack of evidence, but also a theoretical risk of further bleeding into the haematoma causing extension of the dissection, and also infrequent coronary thrombus on angiography (5). Some authors recommend dual antiplatelets acutely (2, 5), for example for two to four weeks (5), although the optimal duration is not known. Often this would be followed by aspirin monotherapy for anywhere between three months (5) to a year (1).

Anticoagulation is likely to have been started once the initial diagnosis of ACS was made, but, like antiplatelets, anticoagulation has the benefit of reducing thrombus burden but also the theoretical risk of worsening bleeding into the haematoma. Anticoagulation is not routinely recommended by the AHA or ESC (1, 2).

Beta-blockers are indicated for management of arrhythmias or LV dysfunction, but some also advocate for their routine use, extrapolating benefit from their use in atherosclerosis and aortic dissection (1, 23). One observational study (24) of 327 patients found a reduced risk of recurrent SCAD with beta-blocker use (hazard ratio 0.36, $p = 0.004$), but these results have not been replicated. There is also no evidence for routine use of statins (1, 12), or ACE inhibitors beyond treatment of LV dysfunction.

Recurrent SCAD

The rate of recurrent SCAD have been variously reported between 10% and 30% (1, 5), although data is complicated by varying definitions and time of follow up of different studies. Generally, recurrence is defined as an apparent new dissection in a location not suggesting extension of prior SCAD, and associated with symptoms and raised troponins (5). The risk factors for recurrence are not well understood, with severe coronary tortuosity being the only identified risk factor (12). The only treatments that have shown benefit in reducing recurrence are beta-blockers, and blood pressure control (5, 24). There has been no association between rates of recurrence and antiplatelet treatment.

Lifestyle advice

Given that a proportion of cases are triggered by physical exertion, understandably some patients are reluctant to resume physical activity. However the literature would suggest that cardiac rehabilitation and moderate exercise is overall of more benefit than harm (1, 2, 5), although it would be advised to avoid extreme endurance training, competitive sports or extremes of temperature.

Pregnancy and SCAD

Patients with pregnancy-associated SCAD tend to have a more severe clinical course (2, 22). The majority of cases occur in the first four weeks post-partum, but can occur at any time during the pregnancy or post-partum (1, 6). Management is largely as for non-pregnant patients, but patients should be managed by a multidisciplinary team including obstetricians. Angiography should not be avoided solely on the basis of fetal radiation concern (5), as the risks of fetal radiation are relatively low and the benefits to mother of early angiography to confirm the diagnosis will outweigh the risks (1). However, there will be special considerations for longer term medications including choice of beta-blockers, and avoidance of ACE-inhibitors.

Despite limited data on outcomes, women are generally advised against pregnancy after SCAD (1), whether the SCAD was directly associated with pregnancy or not. A Mayo Clinic registry study (25) looked at 31 pregnancies in 22 SCAD women resulting in 19 live births, with two patients experiencing recurrence of SCAD but the majority having uncomplicated pregnancies. The sequelae of previous SCAD including LV function will affect individual risk. The theoretical risk of recurrence alongside

the paucity of evidence on outcomes should be shared with women before potentially life-changing advice to avoid pregnancy is given. If pregnancy does occur, these patients are high risk (2) and should be managed with close collaboration between obstetricians and cardiologists.

The association with female sex and pregnancy also gives rise to anxiety about hormonal-based contraception. Although not specifically studied in SCAD patients, progesterone-only methods have been recommended in preference to oestrogen-containing methods (5). Progesterone-containing contraception would also help excessive menstrual blood loss for patients on antiplatelets.

Long term management

Routine repeat invasive angiography is not recommended due to the risk of iatrogenic dissection. It would be indicated only if recurrent symptoms, chest pain with abnormal functional testing, or to confirm healing of high risk lesions, such as left main stem (1). CTCA can be considered in conservatively managed patients with proximal to mid vessel dissections to confirm healing (15), but for more distal lesions CT is often not useful and does carry radiation risk in younger patients.

Given the documented associated with underlying arteriopathies (9), it is recommended by the AHA and ESC that screening for extracoronary vascular abnormalities with CT or MR angiography should be carried out post-SCAD (1, 2). This advice is extrapolated from a study in fibromuscular dysplasia patients which found intracranial aneurysms in 12.9% of 669 FMD patients (26). However, the pattern of extracoronary abnormalities in SCAD patients is not predictable, unlike for example in structural heart disease.

Areas for future research

SCAD is an under-researched area and current guidelines are based on observational and retrospective studies and consensus. Areas for future research include examining the underlying pathophysiology as this is not fully understood. In addition, much more work is needed in determining optimal diagnostic techniques and criteria, indications for revascularisation and the best techniques, identifying risk factors for SCAD, the role of antiplatelets in conservatively-managed patients, and therapy to prevent recurrence.

Conclusion

SCAD is an important differential to consider in patients presenting with ACS. Diagnosis can be challenging, and diagnostic angiography itself carries increased risks. However, it is key that SCAD is differentiated from atherosclerotic ACS early as management in terms of medical therapy and indications for revascularisation are quite different. Conservative management is preferred for clinically stable patients, as revascularisation is high risk. There is little evidence for long term medication or how to prevent recurrence, and considerable future research is needed in this patient group to guide early and long term management.

References

1. Hayes SN, Kim ESH, Saw J *et al.* Spontaneous coronary artery dissection: current state of the science: a scientific statement from the American Heart Association. *Circulation* 2018;137:e523-557
2. Adlam D, Alfonso F, Maas A *et al.* European Society of Cardiology, Acute Cardiovascular Care Association, SCAD study group: a position paper on spontaneous coronary artery dissection. *Eur Heart J* 2018;39:3353-3368
3. Kotecha D, Garcia-Guimaraes M, Premawardhana D *et al.* Risks and benefits of percutaneous coronary intervention in spontaneous coronary artery dissection. *Heart* 2021;107:1398-1406
4. Nakashima T, Noguchi T, Haruta S *et al.* Prognostic impact of spontaneous coronary artery dissection in young female patients with acute myocardial infarction: a report from the Angina Pectoris-Myocardial Infarction Multicentre Investigators in Japan. *Int J Cardiol* 2016;207:341-8
5. Hayes SN, Tweet MS, Adlam D *et al.* Spontaneous Coronary Artery Dissection: JACC State-of-the-Art Review. *J Am Coll Card* 2020;76(8):961-984
6. Elkayam U, Jalnapurkar S, Barakkat MN *et al.* Pregnancy-associated acute myocardial infarction: a review of contemporary experience in 150 cases between 2006 and 2011. *Circulation*. 2014;129:1695–1702
7. Waterbury TM, Tweet MS, Hayes SN *et al.* Early natural history of spontaneous coronary artery dissection. *Circ Cardiovasc Interv* 2018;11(9):e006772
8. Jackson R, Al-Hussaini A, Joseph S *et al.* Spontaneous coronary artery dissection: pathophysiological insights from optical coherence tomography. *J Am Coll Cardiovasc Imaging* 2019;12(12):2475-2488
9. Saw J, Aymong E, Sedlak T *et al.* Spontaneous Coronary Artery Dissection: Association with Predisposing Arteriopathies and Precipitating Stressors and Cardiovascular Outcomes. *Circ Cardiovasc Interv* 2014;7(5):645-655
10. Lobo AS, Cantu SM, Sharkey SW *et al.* Revascularisation in Patients with Spontaneous Coronary Artery Dissection and ST-Segment Elevation Myocardial Infarction. *J Am Coll Cardiol* 2019;74(10):1290-1300
11. Tweet MS, Eleid MF, Best PJM *et al.* Spontaneous coronary artery dissection: revascularisation versus conservative therapy. *Circ Cardiovasc Interv* 2014;7:777-86
12. Eleid MF, Guddeti RR, Tweet MS *et al.* Coronary artery tortuosity in spontaneous coronary artery dissection: angiographic characteristics and clinical implications. *Circ Cardiovasc Interv* 2014;7:656–662
13. Saw J. Coronary angiogram classification of spontaneous coronary artery dissection. *Catheter Cardiovasc Interv* 2014;84:115-1122

14. Tan NY, Hayes SN, Young PM *et al.* Usefulness of cardiac magnetic resonance imaging in patients with acute spontaneous coronary artery dissection. *Am J Cardiol* 2018;122:1624-1629
15. Roura G, Ariza-Solé A, Rodriguez-Caballero IF *et al.* Noninvasive follow-up of patients with spontaneous coronary artery dissection with CT angiography. *JACC Cardiovasc Imaging*. 2016;9:896– 897
16. Hassan S, Prakash R, Starovoytov A *et al.* Natural history of spontaneous coronary artery dissection with spontaneous angiographic healing. *J Am Coll Cardiol Interven* 2019;12:518-527
17. British Cardiovascular Intervention Society. BCIS national audit of adult interventional procedures. Available: <http://bcis.org.uk/audit-results/>
18. Yumoto K, Sasaki H, Aoki H *et al.* Successful treatment of spontaneous coronary artery dissection with cutting balloon angioplasty as evaluated with optical coherence tomography. *JACC Cardiovasc Interven* 2014;7:817-819
19. Alkhouli M, Cole M, Ling FS. Coronary artery fenestration prior to stenting in spontaneous coronary artery dissection. *Catheter Cardiovasc Interven* 2016;88:E23-27
20. Walsh SJ, Jokhi PP, Saw J. Successful percutaneous management of coronary dissection and extensive intramural haematoma associated with ST elevation MI. *Acute Card Care* 2008;10:231-233.
21. Panoulas VF, Ielasi A. Bioresorbable scaffolds and drug-eluting balloons for the management of spontaneous coronary artery dissections. *J Thoracic Dis* 2016;8:E1328-1330
22. Tweet MS, Hayes SN, Codosi E *et al.* Spontaneous coronary artery dissection associated with pregnancy. *J Am Coll Cardiol* 2017;70:426-35
23. Saw J, Mancini GBJ, Humphries KH. Contemporary review on spontaneous coronary artery dissection. *J Am Coll Cardiol* 2016;68:297–312
24. Saw J, Humphries K, Aymong E *et al.* Spontaneous coronary artery dissection: clinical outcomes and risk of recurrence. *J Am Coll Card* 2017;70:1148-1158
25. Tweet MS, Hayes SN, Gulati R *et al.* Pregnancy after spontaneous coronary artery dissection: a case series. *Ann Intern Med* 2015;162(8):598-600
26. Lather HD, Gornik HL, Olin JW *et al.* Prevalence of intracranial aneurysm in women with fibromuscular dysplasia: a report from the US Registry for Fibromuscular Dysplasia. *JAMA Neurol* 2017;74:1081-1087